

RADIOPROTECTIVE EFFICACY OF *ALOE VERA* LEAF EXTRACT

Shailja Pande, Madhu Kumar and Ashok Kumar*

Dept. Zoology, Univ. of Rajasthan, Jaipur, India

ABSTRACT

Radiomodifying effects of the leaf extract of Aloe vera were observed on the testes of Swiss albino mice at 50 and 100 mg/kg dose levels. This extract was non-toxic when injected up to 800 mg/kg, and significant enhancement in survival time of the irradiated group was observed. In addition, treatment reduced radiation-induced damage to germ cells and loss in body weight.

INTRODUCTION

Factors such as increased use of atomic energy increases radiation hazards in human populations. Several programs have been initiated to explore safeguards and protect human beings from radiation damage. During the last decade, intensified studies have been carried out with various compounds to investigate whether administration before or after irradiation protects the organism from harmful effects. However, compounds have yet to be identified without side-effects. Thus, a leaf extract of *Aloe vera* was screened for radiomodifying efficacy.

The genus *Aloe* (Liliaceae) is well known for medicinal properties. Extracts contain various proteins and amino acids, such as serine and asparagine (Nash & Beaumont, 1992). In Ayurvedic medicine, *Aloe vera* is known for a wide spectrum of pharmacological uses such as in the treatment of tumors, liver complaints, skin diseases and ulcers.

Aloe vera gel was first used by Collins and Collins in 1935 for the treatment of radiodermatitis. The gel,

which contains acemannan, reduces acute radiation-induced skin reactions. In wound dressing, this gel exerts a significant radioprotective effect when applied topically, without any observable toxic effects. Thus, it was hypothesized that this extract would be useful as a clinical adjunct to radiotherapy (Roberts & Travis, 1995).

In the present study, an attempt was made to assess modification of radioresponses in the testes of Swiss albino mice with a leaf extract of *Aloe vera*. Radiation sickness, mortality and testicular cell population were measured. The proliferative germ cell layer is affected significantly by irradiation, since proliferating and differentiating cells are radiosensitive. Further, damage in germ cells could be transferred to the next generation and affect the progeny cells.

MATERIALS AND METHODS

Animals

Swiss albino mice (6–8 weeks old) were used for the present study. Animals were given standard mouse feed and water *ad libitum*. The colony was maintained at a room temperature of $25 \pm 2^\circ\text{C}$ and a light:dark exposure of 12 h:12 h.

Source of Irradiation

Animals were irradiated with a Co^{60} source at SMS Medical College, Jaipur, India. For irradiation, the animals were kept in a ventilated plastic box at a distance of 80 cm from the source. The dose rate of the source at this distance was 1.69 Gy/min.

Extract

A leaf extract of *Aloe vera* was obtained from Amsar Pvt. Ltd., Indore, India, in dry powdered form. It was dissolved in distilled water before injection.

Keywords: *Aloe vera*, radioprotection, testis.

* Author to whom correspondence should be addressed.

Design of Experiment

Animals were given *Aloe vera* extract daily over 4 days via intraperitoneal (injection i.p. in 0.1 ml of distilled water. On the last day (i.e. day 4) they were irradiated 30 min after the injection, and this day was considered as day zero. Animals were then autopsied on days 1, 3, 7, 14, and 30. Testes were removed and processed for histopathological observations. Other parameters studied were animal body weight, testes weight and mortality.

To evaluate radiation effects, radioprotective efficacy, and toxicity of this *Aloe vera* extract, animals were divided into different groups as follows:

GROUP I: Normal animals receiving only 0.1 ml distilled water as vehicle i.p.

GROUP II: To evaluate the acute toxicity of the *Aloe vera* extract, it was injected at doses of 50, 100, 200, 400, 600, and 800 mg/kg body weight to different subgroups of animals.

GROUP III: To evaluate the toxic effects of the *Aloe vera* extract over 30 days, two dose levels, i.e., 50 and 100 mg/kg, were given to two groups of animals.

GROUP IV: For a radiation-treated control study, animals were exposed to a $LD_{50/30}$ dose of radiation, i.e., 8 Gy on day zero without any other treatment.

GROUP V: To study radioprotective efficacy, the *Aloe vera* extract was injected at 50 and 100 mg/kg dose levels, and on day zero, animals were irradiated with 8 Gy γ -radiation.

RESULTS

Drug Toxicity

Acute toxicity of the leaf extract of *Aloe vera* was tested by administering 50, 100, 200, 400, 600, and 800 mg/kg dose levels. No mortality or toxic effects were observed within 24 h of injection. However, at the highest dose level, animals started dying 33 h after injection. Thus, selection of the non-toxic 50 and 100 mg/kg doses were used for determination of long term toxicity, the animals were studied for 30 days after administration. At these two dose levels all the treated animals survived until the termination of the experiment

Radiation Effects

Exposure of animals to a lethal dose of radiation (8 Gy) caused anorexia, epilation, diarrhoea, weight loss and lethargy. About 70% of the animals died within 30 days. Mortality started from 4 days onwards, and maximum mortality occurred on day 13. In this group, animal weight remained unchanged. However, testes weight

and tubular diameter decreased significantly $p < 0.001$ (Table 1). Further, spermatogonia and spermatocytes were degenerated and their population was depleted (Table 3). A high degree of vacuolation in the tubules was observed on day 7 (Fig. 2). Pyknosis was observed in a few spermatogonia and spermatocytes. Exfoliation in the tubules was noted and the lumen was obliterated with damaged or necrotic cells. The interstitium was filled with edematous fluid (Fig. 3). Tubular shrinkage and the intertubular spaces were increased (Fig. 4).

Combined Effects of *Aloe vera* and Radiation

When *Aloe vera* was administered at doses of 50 or 100 mg/kg prior to irradiation, mortality was 10 and 20%, respectively, within 30 days. Symptoms of radiation sickness were diminished over 30 days of observation.

Animal Weight

Animal weight did not show a significant change in any of the groups except on day 30 in the groups treated with 50 or 100 mg/kg extract, where it increased significantly (Table 1).

Testes Weight

Weight of testes increased in the *Aloe vera* treated group on days 14 and 30 (in A50 group) as compared to controls. In the irradiated groups it was reduced on days 7, 14, and 30. However, it increased at all the autopsy intervals in the A50+R and A100+R groups.

Tubular Diameter

Tubular diameter was increased in the A50+R and A100+R group as compared to controls. In the A50+R and A100+R groups, the tubular diameter increased significantly when compared to the irradiated control ($p < 0.001$) at the lower dose, i.e., 50 mg/kg (Table 1).

Quantitative and Qualitative Changes in Various Cell Types

The following quantitative and qualitative changes (Tables 2 and 3) in various cell types were noted.

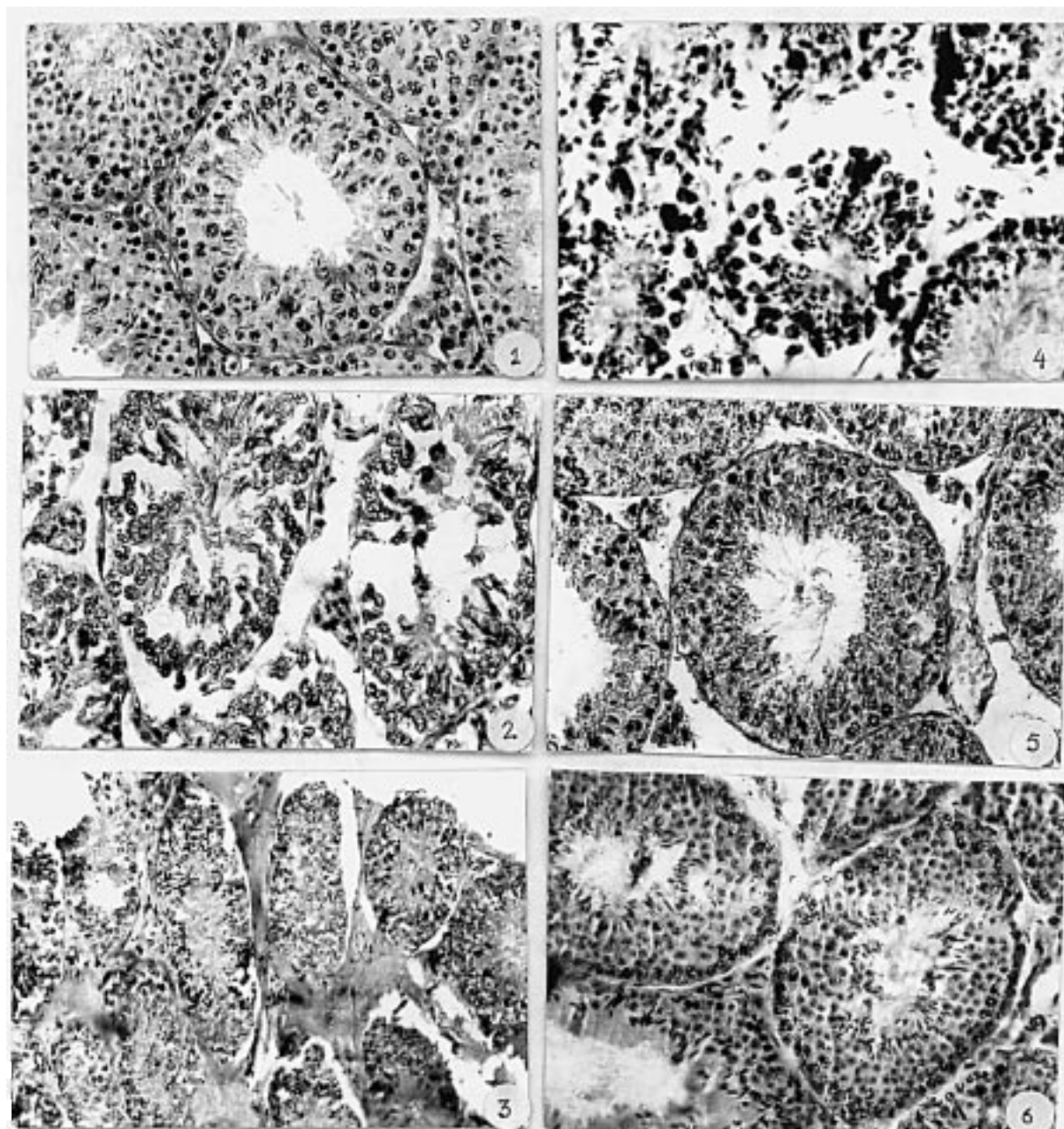
A. Spermatogonia Type A. The irradiated group showed a significant decrease in the count of spermatogonia type A, which increased in both the drug treated groups. The change was significant on days 7, 14 and 30 in the A100+R group.

B. Spermatogonia Type B. In the irradiated group, a significant decrease in the number of spermatogonia type B was observed as compared to controls. No significant change at any autopsy interval was noticed

except on days 1 and 3. However, this effect did not remain constant in the A100+R group.

Cytological studies showed a wide spectrum of damage in both spermatogonia type A and B in the irradiated control animals. However, animals of groups A50+R and A100+R showed evidence of recovery in terms of depletion, degeneration and pyknotic cells (Figs. 5 and 6).

C. Primary and secondary spermatocytes. The number of primary and secondary spermatocytes was normal in the *Aloe vera* treated group. Significant increases in the numbers were observed in the A50+R and A100+R treated groups as compared to the irradiated control. The higher dose was found to be more effective. Pyknosis, karyorrhexis and karyolysis were observed in the irradiated group (Figs. 2, 3, 4).



Figs. 1–6. Photomicrographs of testis of Swiss albino mice showing various histopathological changes after irradiation, with or without *Aloe vera* pretreatment, as follows. (1) Normal architecture of testis, (2) Shrinkage in tubule, cytoplasmic arrest and vacuolation in irradiated (R), group on day 7, (3) shrinkage and edematous fluid in the interstitium in irradiated (R), group on day 14, (4) shrunken and disorganised tubule with increased interstitium in irradiated (R), group on day 30, (5) A₅₀+R, group on day 7 showing normal histology, however, spermatogonial population is depleted, (6) photomicrograph showing active spermatogenesis with all stages and normal interstitium in A₁₀₀+R, group on day 30.

(D) *Spermatids*. The number of spermatids was increased at both doses of *Aloe vera* extract treatment. In the irradiated group, the number of spermatids was reduced. In both the A50+R and A100+R groups there was a significant increase in the number of spermatids. However, quantitatively, the higher dose was found more effective as spermatids did not exhibit any damage.

DISCUSSION

One of the principle effects of whole body exposure to ionizing radiation, in addition to reducing lifespan, is radiation sickness, which includes CNS, GI and haematopoietic syndromes. Acute radiation doses affect the CNS leading to death within 2 days of expo-

Table 1. Variation in the body weight (g) tissue weight (mg), tubular diameter (μm) of adult male Swiss albino mice after the *Aloe vera* (A), radiation (R) and *Aloe vera* + radiation treatment (A + R).

Experimental group	Parameter	Autopsy interval (days)				
		1	3	7	14	30
A ₅₀	Body weight	20.60 ± 0.45	21.10 ± 0.34	20.80 ± 1.30	21.9 ± 0.34	23.5 ± 0.42
	Testis weight	88.30 ± 2.49 ⁺	85.8 ± 2.44	85.1 ± 1.33	109.7 ± 4.14 ⁺⁺⁺	104.7 ± 1.66 ⁺⁺⁺
	Tubular diameter	178.74 ± 4.79 ⁺	186.39 ± 2.91 ⁺⁺	181.39 ± 5.05 ⁺	199.67 ± 4.98 ⁺⁺⁺	174.67 ± 2.65
A ₁₀₀	Body weight	21.50 ± 0.63	19.80 ± 1.16	21.90 ± 0.60	21.40 ± 0.86	21.5 ± 0.47
	Testis weight	92.6 ± 2.57 ⁺⁺	86.9 ± 1.76	85.1 ± 0.82	86.3 ± 1.30	88.5 ± 2.16
	Tubular diameter	185.96 ± 3.48 ⁺⁺	206.72 ± 6.22 ⁺⁺⁺	172.87 ± 7.33	183.35 ± 3.83 ⁺⁺	186.83 ± 2.66 ⁺⁺
R(8Gy)	Body weight	19.55 ± 0.88	18.95 ± 0.77	18.20 ± 0.85	17.7 ± 0.83	15.7 ± 0.82
	Testis weight	74.40 ± 2.53	74.4 ± 2.13	59.80 ± 2.66 ⁺⁺	46.6 ± 2.59 ⁺⁺⁺	25.9 ± 1.07
	Tubular diameter	145.72 ± 1.35	131.06 ± 3.28	127.56 ± 2.49	126.31 ± 1.91	126.15 ± 2.31
A ₅₀ + R	Body weight	20.50 ± 0.42	17.90 ± 1.71	20.60 ± 2.38	20.30 ± 0.53	23.8 ± 0.97 ⁺⁺⁺
	Testis weight	75.6 ± 1.10	8.71 ± 2.74 ⁺	72.4 ± 2.80 ⁺⁺	49.0 ± 1.86	30.9 ± 2.12
	Tubular diameter	185.74 ± 2.56 ⁺⁺⁺	166.61 ± 5.38 ⁺⁺⁺	158.79 ± 4.32 ⁺⁺	151.98 ± 5.38	182.37 ± 3.79 ⁺⁺⁺
A ₁₀₀ + R	Body weight	21.30 ± 0.53	19.80 ± 0.46	22.00 ± 0.83 ⁺⁺	18.80 ± 0.66	26.90 ± 0.54 ⁺⁺
	Testis weight	91.11 ± 2.85 ⁺⁺	78.0 ± 1.57	67.40 ± 1.58 ⁺	56.9 ± 1.58 ⁺⁺	39.5 ± 0.94 ⁺⁺
	Tubular diameter	155.34 ± 2.42	141.19 ± 1.49	138.69 ± 2.76	152.90 ± 2.62 ⁺	150.29 ± 1.89 ⁺⁺
Normal ¹	Animal weight	21.20 ± 0.488				
	Testis weight	76.5 ± 1.021				
	Tubular diameter	157.4 ± 2.90				

¹Average animal weight, tissue weight and tubular diameter measured on each autopsy interval.

+++ $p < 0.001$, ++ $p < 0.01$, + $p < 0.05$.

Table 2. Variation in different cell counts of seminiferous tubule of the testes of adult male Swiss albino mice at various autopsy intervals in only *Aloe vera* (A) treated groups.

Experimental group	Cell types	Autopsy interval (days)				
		1	3	7	14	30
A ₅₀	Spermatogonia type A	6.00 ± 0.59	3.60 ± 0.58	1.60 ± 0.40	2.90 ± 0.37	8.80 ± 0.32
	Spermatogonia type B	6.60 ± 0.63	4.40 ± 0.54	3.70 ± 0.37	3.40 ± 0.52	6.20 ± 0.77
	Primary spermatocytes	27.20 ± 1.57	39.00 ± 1.10 ⁺	34.80 ± 0.72	37.70 ± 1.13	47.70 ± 1.26 ⁺⁺
	Secondary spermatocytes	20.30 ± 1.53	25.70 ± 1.65	20.90 ± 1.25	22.80 ± 1.22	28.30 ± 1.92
	Spermatids	48.20 ± 1.58 ⁺⁺⁺	27.50 ± 0.95	21.90 ± 1.43	19.10 ± 0.73	27.20 ± 2.26
A ₁₀₀	Spermatogonia type A	2.77 ± 0.49	4.11 ± 0.40	2.55 ± 0.55	0.40 ± 0.22	5.66 ± 0.44
	Spermatogonia type B	7.88 ± 0.73	6.11 ± 0.67	5.54 ± 0.68	2.22 ± 0.54	3.11 ± 0.48
	Primary spermatocytes	36.50 ± 2.53	46.44 ± 1.73 ⁺⁺	42.66 ± 0.86 ⁺⁺	38.00 ± 0.86 ⁺⁺	45.77 ± 1.30 ⁺⁺
	Secondary spermatocytes	21.33 ± 1.28	23.44 ± 2.24	28.55 ± 1.87	19.44 ± 1.38	17.66 ± 0.83
	Spermatids	38.11 ± 2.02 ⁺⁺	36.55 ± 1.84	36.88 ± 2.64 ⁺	20.55 ± 1.06	37.72 ± 0.97
Normal ¹	Spermatogonia type A	10.60 ± 0.30				
	Spermatogonia type B	13.10 ± 0.79				
	Primary spermatocytes	31.50 ± 1.87				
	Secondary spermatocytes	47.40 ± 2.12				
	Spermatids	30.00 ± 0.71				

¹Average number of cells counted on each autopsy interval.

+++ $p < 0.001$, ++ $p < 0.01$, + $p < 0.05$.

Table 3. Variation in different cell counts of seminiferous tubule of testes, of adult male Swiss albino mice at various autopsy intervals in irradiated group (R) and *Aloe vera* + radiation treatment (A + R).

Experimental group	Type of cell	Autopsy interval (days)				
		1	3	7	14	30
R(8Gy)	Spermatogonia type A	2.77 ± 0.49	6.00 ± 0.59	0.44 ± 0.22	4.00 ± 0.22	6.88 ± 0.81
	Spermatogonia type B	3.00 ± 0.33	5.66 ± 0.63	4.77 ± 0.44	5.33 ± 0.83	13.33 ± 1.27
	Primary spermatocytes	22.55 ± 0.93	35.44 ± 2.13	17.77 ± 2.13	7.00 ± 0.63	18.55 ± 1.63
	Secondary spermatocytes	12.66 ± 1.11	19.66 ± 1.09	29.33 ± 5.00	13.22 ± 1.68	20.66 ± 1.20
	Spermatids	45.12 ± 1.22	33.44 ± 2.76	26.44 ± 2.88	25.55 ± 2.51	0.00 ± 0.00
A +R(8 Gy)	Spermatogonia type A	2.60 ± 0.30	3.20 ± 0.41	2.20 ± 0.41 ++	4.10 ± 0.48	2.20 ± 0.35
	Spermatogonia type B	4.00 ± 0.33	2.80 ± 0.41	2.80 ± 0.41	1.90 ± 0.37	1.60 ± 0.47
	Primary spermatocytes	28.20 ± 1.35 +++	26.60 ± 0.95	11.60 ± 0.95	7.30 ± 0.59	17.60 ± 0.56
	Secondary spermatocytes	17.40 ± 0.70 +	17.20 ± 1.36	17.20 ± 1.31	17.20 ± 1.63	22.00 ± 0.68
	Spermatids	33.20 ± 1.19	40.50 ± 1.41 ++	24.50 ± 1.49	13.60 ± 0.88	26.00 ± 0.47 +++
A 100 +R(8 Gy)	Spermatogonia type A	6.70 ± 0.47 ++	5.22 ± 0.30	3.60 ± 0.04 +++	13.50 ± 0.80 +++	13.30 ± 0.63 +++
	Spermatogonia type B	10.30 ± 0.59 ++	15.11 ± 1.56 +++	6.20 ± 0.41 +	4.50 ± 0.72	5.90 ± 0.98
	Primary spermatocytes	42.60 ± 0.88 +++	50.66 ± 0.86 ++	48.77 ± 0.90 +++	39.00 ± 1.07 +++	45.00 ± 1.31 +++
	Secondary spermatocytes	21.44 ± 0.96 +++	36.66 ± 0.72 ++	13.22 ± 1.34	26.11 ± 2.16 +++	27.40 ± 1.02 ++
	Spermatids	55.66 ± 0.96 ++	52.40 ± 1.56 +++	56.00 ± 1.37 +++	34.90 ± 1.51 ++	42.80 ± 2.67 +++
Normal ¹	Spermatogonia type A	10.60 ± 0.30				
	Spermatogonia type B	13.10 ± 0.79				
	Primary spermatocytes	31.50 ± 1.87				
	Secondary spermatocytes	47.40 ± 2.12				
	Spermatids	30.00 ± 0.71				

¹Average number of cells counted on each autopsy interval.

+++ $p < 0.001$, ++ $p < 0.01$, + $p < 0.05$.

sure. Further, damage in crypt cell populations affects the villi and absorption of water and electrolytes and influences total animal body weight. This may cause a GI syndrome or even death within 3–7 days of irradiation (Lushbaugh et al., 1960; Takeda, 1962). Death after 7 days of exposure may be associated with the haematopoietic syndrome and includes hemorrhage, infection and fluid imbalance (Woods et al., 1953; Hjort et al., 1959). In this study, these classical radiation born syndromes were observed when animals were exposed to 8 Gy whole body irradiation.

In the irradiated animals, a gradual loss in testes weight was observed. This may be related to actual loss in the number of germinal cells (Kohn & Kallman, 1954, 1955). In the present study, a significant decrease was found in the number of germinal cells in the irradiated group. This destruction at a specific stage of cell division caused disruption in the maturation process of the organ and therefore the number of immature cells were increased, leading to a loss in testes weight. The loss of cells also affects testosterone levels which ultimately disturb the maintenance of gonads (Wang et al., 1983).

A histopathological study of the irradiated animals tested revealed various pathological changes such as pyknosis, karyorrhexis, karyolysis and cytoplasmic vacuolation leading to apoptosis of affected cells. In

addition, loss of germinal epithelium, inter-tubular edema and shrinkage in the tubular diameter was also observed (Fig. 2).

However, *Aloe vera* leaf extract pretreatment was found to improve body weight, survival time and reduce the incidence of abnormalities in cells of the testes, significantly, at both tested dose levels (i.e., 50 and 100 mg/kg). The lower dose (50 mg/kg) was found to be more effective where 90% of the animals survived for more than 30 days, as compared to higher dose (100 mg/kg) where only 80% of the animals survived for 30 days. This effect can be correlated to free radical scavenging properties and glutathione peroxidase activity (Sato et al., 1990). However, the mode of radioprotection of *Aloe vera* could not be established, since no single definite active ingredient has been identified to date. It is commonly suggested that there may be some synergistic reaction taking place between various components and polysaccharides which is responsible for the action (Leung, 1977, 1978; Henry, 1979). It may be possible that a moisturizing and emollient ability of *Aloe vera* may also enhance its radioprotective efficacy (Spoerke & Ekins, 1980; Meadow, 1980), *Aloe* leaves also contain compounds such as lectin which can enhance the growth of normal human cells (Winters et al., 1981). Recent research indicated that *Aloe* gel has

antiprostaglandin effects which may also influence the immune system (Raine et al., 1980; Hegggers et al., 1993). In addition to all these effects, *Aloe vera* extract can also protect radiation caused bacteremia (Bruce, 1967). This variety of biological activities makes *Aloe* worthy of further screening as a radioprotective agent.

ACKNOWLEDGEMENT

Department of Zoology, University of Rajasthan, Jaipur (India) and Amsar Pvt. Ltd., Indore (India) are gratefully acknowledged for a JRF award to Shailja Pande and for the supply of *Aloe vera* extract, respectively.

REFERENCES

- Bruce WCG (1967): Investigation of the antibacterial activity in the *Aloe*. *S Afr Med J* 41: 984.
- Collins CE, Collins C (1935): Roentgen dermatitis treated with fresh whole leaf of *Aloe vera*. *Am J Roentgenol* 33: 396–397.
- Hegggers JP, Pelley RP, Robson MC (1993): Beneficial effects of *Aloe* in wound healing. *Phytother Res* 7: 548–552.
- Henry R (1979): An updated review of *Aloe vera*. *Cosmet Toilet* 94: 42–50.
- Hjort PF, Perman V, Cronkite EP (1959): Fresh disintegrated platelets in radiation thrombocytopenia, Correction of prothrombin consumption without correction of bleeding. *Proc Soc Exp Biol Med* 102: 31.
- Kohn HI, Kallman RF (1954): Testis weight loss as a quantitative measure of X-ray injury in the mouse, hamster and rats. *Br J Radiol* 27: 586.
- Kohn HI, Kallman RF (1955): The effect of fractionated X-ray dosage upon the mouse testes. I. Maximum weight loss following 80 to 240 R given in 2 to 5 fractions during 1 to 4 days. *J Natl Cancer Inst* 15: 891.
- Leung AY (1977): *Aloe vera* in cosmetics. *Drugs Cosmetic Ind.* 120: 154–155.
- Leung AY (1978): *Aloe vera* in cosmetics. *Excelsa* 8 65–68.
- Lushbaugh CC, Sutton J, Richmond CR (1960): The question of electrolyte loss in the intestinal death syndrome of radiation damage. *Radiat Res* 13: 814.
- Meadow TP (1980): *Aloe* as a humectant in new skin preparations. *Cosmet Toilet* 95: 51–56.
- Nash RJ, Beaumont J (1992): Phenylethylamine and piperidine alkaloids in *Aloe* species. *Planta Med* 52: 87.
- Raine TJ, London MD, Goluch K, Hegggers JP et al. (1980): Antiprostaglandins and antithromboxanes for treatment of frostbite. *Am Coll Surg Surgic Forum* 31: 557–559.
- Roberts DB, Travis L (1995): Acemannan containing wound dressing gel reduces radiation induced skin reactions in C₃H mice. *Int J Rad Oncol Biol Phys.* 32: 1047–1052.
- Sato Y, Ohta S, Shinoda M (1990): Studies on chemical protectors against radiation XXXI. Protection effects of *Aloe arborescens* on skin injury induced by X-irradiation. *Yakugaku Zasshi* 110: 876–884.
- Spoerke DG, Ekins BR (1980): *Aloe vera* fact or quackery. *Vet Human Toxicol* 22: 418–424.
- Takeda ST (1962): Water, electrolytes and antibiotic therapy against acute (3 to 5 days) intestinal radiation death in the rat. *Rad Res* 16: 312.
- Wang J, Galil KA, Secthell BP (1983): Changes in testicular blood flow and testosterone production during spermatogenesis after irradiation. *J Endocrinol* 98: 35–46.
- Winters WD, Benavides R, Clouse WJ (1981): Effects of *Aloe* extracts of human normal and tumour cells *in vitro*. *Econ Bot* 35: 89–95.
- Woods MC, Gamble FN, Furth J, Bigelow RR (1953): Control of post-irradiation haemorrhagic state by platelet transfusions. *Blood* 8: 545.

Accepted: March 27, 1998